

Assessment of EUS for diagnosing, staging, and determining resectability of pancreatic cancer: a review

Gordon C. Hunt, MD, Douglas O. Faigel, MD

Portland, Oregon

Pancreatic cancer has a dismal prognosis, but surgery offers a potential for cure in a minority of patients with localized disease. An in-depth review by Gudjonsson¹ of 4100 patients with pancreatic tumor resection found a 5-year survival rate of 3.5%. More recent studies have found improved 5- and 7-year survival rates of 19% and 11%, respectively, in highly selected surgical patients.² This may be due to several factors, including improved surgical technique, the use of adjuvant chemoradiation, earlier diagnosis, and more extensive preoperative staging.

Improved preoperative staging theoretically benefits patient selection for surgery. EUS has been one of the most sensitive tests for detecting pancreatic masses, and it is an accurate modality for the evaluation and staging of pancreatic cancer (Fig. 1). In most reports, T-stage accuracy varies from 78% to 94% and N-stage accuracy ranges from 64% to 82%.³⁻⁸ A recent retrospective review by Ahmad et al.⁹ found lower T- and N-staging accuracies of 69% and 54%, respectively. A majority of tumors in this study were of advanced T-stage (T3 or T4), and these investigators hypothesize that peritumoral inflammation and large tumor size may affect US attenuation and thus, T- and N-staging accuracy. This is supported by previous studies, which indicate that EUS is more effective in detecting vascular involvement in tumors less than 3 cm in size.^{10,11} In their study, Ahmad et al.⁹ fail to define the number of patients excluded because of the discovery by EUS of significant vascular invasion or metastatic disease, precluding surgery. Factoring this additional cohort of patients into the denominator of T- and N-staging would have improved their accuracy rates.

Sensitivity for detecting vascular invasion and predicting surgical resectability has been greater than 90% in some studies.^{3,4,12} Vessels typically invaded by cancer in the head of the pancreas are

From Oregon Health and Science University, Portland Veteran's Affairs Medical Center, Portland, Oregon.

Reprint requests: Douglas O. Faigel, MD, Division of Gastroenterology (P3GI), Portland VAMC, Portland OR 97201.

37/1/121342

doi:10.1067/mge.2002.121342

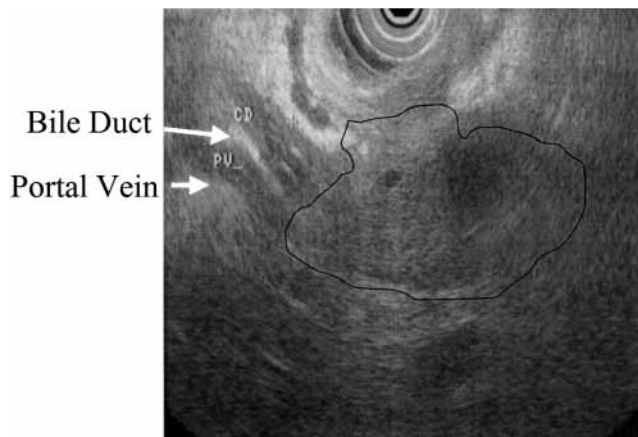


Figure 1. EUS image of carcinoma of the head of the pancreas invading the common bile duct and portal vein.

the portal vein and splenoportal confluence, superior mesenteric vein, and splenic vein; and the superior mesenteric artery, splenic artery, hepatic artery, and celiac axis. Generally, it may be difficult to visualize invasion of the superior mesenteric artery and vein with EUS, but portal vein and splenic vein invasion are well seen.^{12,13} A study by Brugge et al.¹⁴ confirmed the inadequacy of EUS in the determination of superior mesenteric vein involvement but found EUS to be superior to angiography in determining portal and splenic vein invasion with tumor, with accuracy ranging from 77% to 85%, depending on criteria for involvement. In a prospective study of 38 patients with pancreatic neoplasm by Snady et al.,¹⁵ all 21 patients exhibiting either peripancreatic collaterals, loss of vessel interface, or tumor within the lumen of a major peripancreatic vessel had confirmed vascular invasion at surgery, and the absence of these features in the remaining 17 patients was associated with absence of vascular invasion at surgery.

A potential fault of EUS is that accuracy in predicting vascular invasion may be falsely elevated because endosonographers have access to previous image studies, such as standard or helical CT, magnetic resonance imaging (MRI) or magnetic resonance cholangiopancreatography, or angiography. Thus, there may already be suspicion of vascular invasion because of examination bias introduced by availability of other information. This has been studied by review of EUS videotapes of cancers of the pancreatic head.¹³ In this study by Rösch et al., EUS videotapes of pancreatic head cancers staged from 1991-95 were retrospectively reviewed in 1997 with regard to vascular invasion. Sensitivity and specificity of EUS in the diagnosis of venous invasion were 62% and 79%, respectively. These values were much lower than those of previous studies,

Table 1. EUS versus standard CT for pancreatic cancer

	EUS	CT	Reference
Detection	94%-100%	69%-85%	(3,4,12)*, (17)
T-stage accuracy	82%	30%-45%	(3)*, (17)
N-stage accuracy	64%-72%	50%-55%	(3)*, (17)
Vascular invasion	92%-95%	62%-75%	(3,4,12)*

*Comparisons are statistically significant.

Table 2. Helical CT versus EUS for pancreatic cancer

Non-GI		GI	
Legmann et al. (n = 30) ²²	CT = EUS	Tierney et al. (n = 51) ²³	EUS >CT
Midwinter et al. (n = 48) ²¹	CT = EUS	Mertz et al. (n = 35) ²⁴	EUS >CT

Table 3. Summary of studies comparing EUS to helical CT for pancreatic cancer

Series	Detection		Accuracy for resectability		Sensitivity for vascular invasion	
	EUS	CT	EUS	CT	EUS	CT
Legmann et al. ²²	27/27	25/27	20/22	19/22	6/7	7/7
Midwinter et al. ²¹	33/34	26/34	25/30	23/30	13/16	9/16
Tierney et al. ²³			30/31	25/31	16/16	10/16
Mertz et al. ²⁴	29/31	16/31	16/16	13/16	6/6	3/6
Total	97%	73%	91%	83%	91%	64%
p Value*	<0.001		0.02		<0.001	

*Fisher exact test.

including studies from the same group, which have reported sensitivity ranging from 88% to 100% and specificity from 78% to 97%.^{4,8,12} Previous studies, however, included cancers in all areas of the pancreas. The study by Rösch et al.¹³ only included cancers of the pancreatic head, a more difficult area to stage. Unlike real-time examination, videotapes are of lower quality and may be artificial, potentially missing some important sequences of staging. Differences may exist between examiners' interpretations of the videotapes. Also, the videotapes were created during the early stages of the investigators' experience with EUS staging of pancreatic cancer, although it is noted that each examiner performed more than 300 pancreatic cases.

EUS VERSUS HELICAL CT

Helical CT is an advance in CT technology that allows for more rapid acquisition of CT images. In standard CT, the x-ray source rotates around the patient to obtain a transverse image while the patient holds his or her breath. The x-ray source then needs to "unwind" to reset for the next image, which is taken during another breath hold. In helical CT there is continuous activation and spinning of the x-ray source and continuous movement of the tabletop. Conventional CT, then, obtains images in a start-stop manner, whereas with helical CT there is continuous data acquisition.¹⁶ The limited capabilities of conventional CT have been compared with EUS in predicting vascular invasion, and EUS has proven to be more accurate^{3,4,12,17} (Table 1).

With helical CT, thinner slices can be obtained in a single breath hold through reconstruction of over-

lapping sections, thus avoiding potential gaps in imaging. The rapid image acquisition allows scanning during different phases of contrast injection to selectively opacify arteries, veins, or the portal venous system. Helical CT therefore provides consistently higher levels of circulating contrast material, allowing more accurate assessment of the splanchnic vessels.¹⁸ Computer algorithms that allow 3-dimensional reconstruction are also possible (such as for virtual colonoscopy). Helical CT angiography has been described and may be better than axial helical CT imaging for detecting vascular invasion.¹⁹

Initial studies reported in radiologic publications found helical CT to have an extremely high detection rate for pancreatic tumors (97%) and to be accurate in predicting unresectability (91%) and vascular invasion (88%).²⁰ This suggested that helical CT was at least as accurate as EUS for the detection and locoregional staging of pancreatic cancer.

There have been 4 studies comparing EUS with helical CT for pancreatic cancer. Two of these appeared in non-gastroenterology publications, and 2 are in *Gastrointestinal Endoscopy* (Table 2).²¹⁻²⁴ Non-GI publications found helical CT and EUS to be roughly equivalent (although Midwinter et al.²¹ found a higher detection rate for small tumors with EUS); and the 2 other studies found EUS to be superior for tumor detection and staging.^{23,24} The discrepancies in findings in these studies may have several causes. Commonly, patients are referred for EUS because no tumor is seen on CT, whereas radiologic studies may rely on CT databases to identify patients for inclusion. Surgery should be used as the reference standard. Although surgery is the most

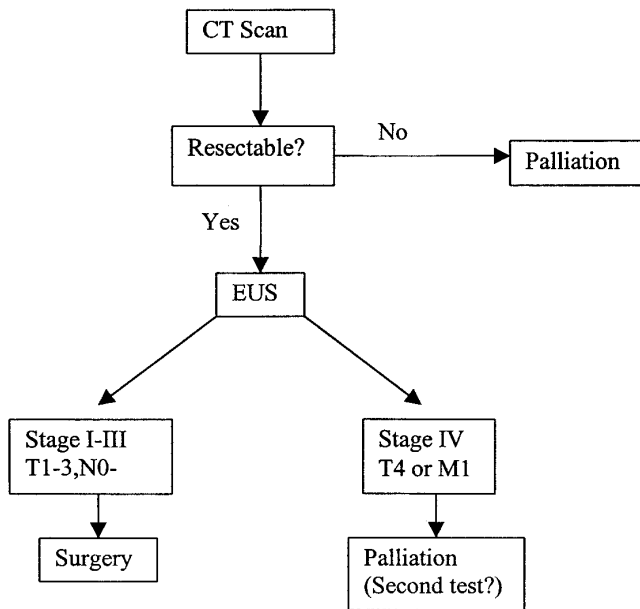


Figure 2. Staging and treatment algorithm for pancreatic cancer.

accurate standard, relying on surgery may result in a skewed population that has had extensive diagnostic testing before arriving in the operating room. Experience with EUS and fine needle aspiration (FNA) technique is also important. Helical CT should be performed with optimal protocols and reconstructions, and specialists should interpret these studies. For example, there may have been a lower accuracy of helical CT in the study of Tierney et al. because of the section thickness of 5 mm in the study compared with conventional 3.2-mm thick slices in other studies.²¹⁻²³ Finally, there is the issue of bias: authors will be biased in favor of their own procedure. In the studies of Legmann et al.²² and Midwinter et al.,²¹ patients with helical CT evidence of distant metastatic disease were included, a clear bias in favor of helical CT.^{21,22} Analyzing and combining the data may help put these results in perspective. Because half of these studies are non-GI and half are GI, this type of analysis may negate some of the effects of bias. The analysis shown in Table 3 demonstrates that EUS remains the most sensitive test for detecting small tumors in the pancreas. For determining whether the tumor is resectable, helical CT has good accuracy (83%) although EUS is somewhat better (91%). The improved accuracy of EUS is due to its greater sensitivity for detecting vascular invasion of the portal venous system.

A suggested algorithm for the evaluation and treatment of patients suspected to have pancreatic cancer is shown in Figure 2. A similar algorithm has

been prospectively assessed and found to be accurate in predicting cancer stage and to correlate well with prognosis.²⁵

EUS VERSUS OTHER IMAGING TECHNIQUES

When EUS has been directly compared with angiography in defining vascular involvement in pancreatic adenocarcinoma, EUS was found to be significantly more sensitive.^{14,26} In a retrospective comparison of MRI versus EUS in staging and determination of resectability of pancreatic cancer, neither imaging modality when used alone was sufficient for determining resectable from unresectable tumors, but when both tests agreed on resectability, nearly all patients (89%) were found to have resectable tumors on surgical exploration.²⁷ However, a small prospective study found EUS to be numerically superior to MRI for the detection and tumor staging of pancreatic neoplasms, but roughly equivalent for assessment of lymph nodes.¹⁷ Two academic institutions evaluated EUS, helical CT, MRI, and selective angiography for evaluation of ampullary neoplasms. EUS was more accurate than CT and MRI in the assessment of T-stage, but EUS T-staging accuracy decreased from 84% to 72% in the presence of a transpapillary endobiliary stent.²⁸ EUS and helical CT have also been compared with positron emission tomography (PET) for sensitivity in the detection of pancreatic cancer.²⁴ EUS and PET were shown to be more sensitive than helical CT in identifying pancreatic cancer as a primary tumor, though an additional value of PET is the identification of unresectable or metastatic disease. PET scanning clarifies equivocal CT abnormalities seen in the liver.

Whether helical CT, MRI, angiography, PET, or EUS staging procedures ultimately lead to improved disease-free survival remains unknown. Future trials should address this issue.²²

EUS-GUIDED FNA

FNA of the pancreas can be performed under either CT or EUS guidance. The advantage of EUS is that FNA is generally performed during the same staging procedure. In contrast, CT-guided FNA is invariably performed as a second CT procedure. EUS-FNA can also be performed for small tumors not visible on CT. EUS-FNA is about 75% to 80% sensitive for the diagnosis of pancreatic cancer and carries a small risk of pancreatitis.²⁹⁻³¹ For patients with clear evidence of unresectable disease on helical CT, CT-guided FNA will usually be performed, depending on local expertise and availability.

The major issue in EUS-FNA is the selection of appropriate patients for the procedure. Most experts

agree that patients with unresectable disease should undergo FNA.³² The FNA provides the necessary tissue diagnosis before initiating chemotherapy or radiotherapy. It has been argued that FNA is not necessary for the diagnosis of resectable disease because this would not change management; that is, patients were going to have surgery in any case. Yet, FNA may change management even if resectable disease appears to be present.

One situation in which FNA might have an impact would be if it effectively ruled out cancer. With a sensitivity of 80%, a modality that misses 1/5 of cancers should not be used to rule out carcinoma. But in some instances, a negative FNA will reduce the likelihood of cancer to a low enough level that a choice might be made not to perform surgery. For example, if the risks of surgery were greater than the probability of a patient having resectable disease, then surgery should not be performed.

So what is this break-even point: the point at which the benefits outweigh the risks of surgery? The mortality associated with the Whipple procedure is approximately 5% and major complications occur in another 5% to 10%. Of the patients in whom the tumor is fully resected, fewer than half will be rewarded with a long disease-free survival. Therefore, at least a 25% to 30% chance that our patient has resectable cancer is necessary (5% mortality plus 5%-10% major morbidity multiplied by 2).

To determine whether EUS-FNA will reduce the probability of cancer to less than 25% requires the use of Bayes' theorem (Fig. 3). Consider two examples:

- The first is a patient with painless jaundice, a "double duct" sign, and an obvious mass on imaging. The estimated pretest probability that the patient has cancer would be nearly 90%. If FNA is performed (sensitivity = 80%, specificity = 100%) and is negative, the patient still has a 64% probability of having cancer. Cancer is not ruled out, and surgery should be performed.
- The second is an alcoholic patient with abdominal pain and a poorly defined, possibly inflammatory mass in the pancreas. Estimating the pretest probability at 50% with a negative FNA, the chance that he has cancer is only 17%. In this case with "resectable" disease, the risks of surgery may outweigh the benefits. Therefore, if there is doubt as to the diagnosis of cancer (pretest probability <70%) a negative FNA may effectively "rule out" the need for surgery; that is, the risks of surgery may outweigh the benefits (Fig. 3). Future studies should focus on clinical and endosonographic features predictive of a high pretest probability for cancer.

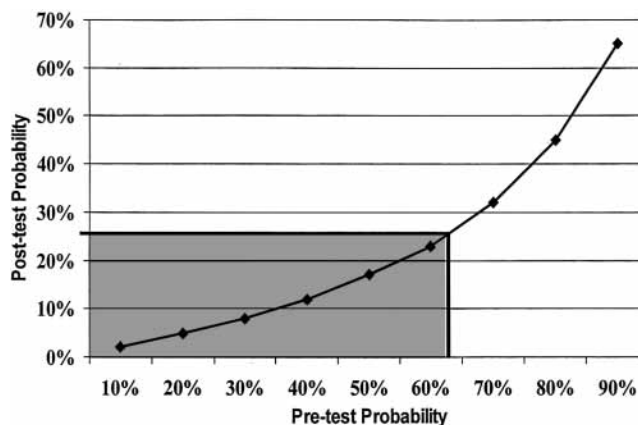


Figure 3. Bayes' theorem: negative EUS-FNA. Assuming EUS-guided FNA has a sensitivity of 80% and specificity of 100% for pancreatic cancer, the post-test probability of a negative EUS-FNA is plotted against the pretest probability of cancer. For pretest probabilities less than 67% (shaded area) the risks of surgery may outweigh the benefits because of the low (<25%) post-test probability of cancer.

The establishment of a histologic diagnosis before surgery can also alter management. Not all pancreatic cancers are adenocarcinomas and some types (lymphomas, small cell carcinomas) are treated non-surgically. Islet cell tumors and papillary cancers are slow growing and have better prognoses than pancreatic adenocarcinoma. They can be successfully removed with organ-preserving resections, particularly islet cell tumors.³³ Even if these slow-growing tumors are found to be incompletely resectable, our preference is to debulk these tumors for palliation and possible survival benefits. Altering the surgical approach in this manner requires that the histopathology be known before surgery, because frozen sections may not be reliable for determining tissue type (especially islet cell tumors, which require special stains). Even with the best preoperative staging, an adenocarcinoma may be found at surgery to be unresectable, in which case a surgical biopsy will be needed (tru-cut needle). Because surgical biopsy itself is only about 80% sensitive for pancreatic masses, a preoperative tissue diagnosis would be desirable.³⁴

Finally, patients (and their doctors) simply want to know whether they have cancer. To properly counsel patients as to treatment options, such as extensive and potentially morbid surgical resections, having a biopsy confirmation of cancer is ideal. EUS-FNA will provide a tissue diagnosis in most patients.³⁰ For these reasons, FNA should be strongly considered in the majority of patients referred for EUS of pancreatic masses.

Cost analyses of EUS in determining unresectable disease have been analyzed. A decision

model found that performing EUS in all patients, followed by laparoscopy in those felt to have resectable tumors, reduced the number of unnecessary surgical explorations by 61% compared with laparoscopy alone. This combination of tests resulted in the lowest cost per surgical resection (\$37,600).³⁵ In another cost-analysis study comparing EUS-FNA versus CT-guided FNA versus surgery in management of nonmetastatic adenocarcinoma of the head of the pancreas, EUS-FNA was the least costly strategy, assuming detection of nonperitumoral lymph nodes at a rate greater than 4%.³⁶ Detection of metastatic lymph nodes will avoid unnecessary surgery, estimated in this study to be 16 unnecessary surgeries per 100 patients evaluated with EUS-FNA. Unsuspected mediastinal metastases are found on EUS in up to 7% of patients and can be sampled by means of EUS-FNA.³⁷

SUMMARY

EUS is a highly sensitive test for detecting small pancreatic masses and is accurate in determining vascular invasion of the portal venous system, a major determinant of resectability. Helical CT is an advance over standard CT in its ability to detect and stage pancreatic cancer and should be performed before EUS to rule out metastatic and obviously unresectable cancer. EUS should be performed when no unresectable disease is found or if a tumor is not visualized, although suspected. PET scanning may be a useful adjunct to detect occult metastatic disease, and MRI or angiography may be used to confirm vascular invasion in selected patients. EUS staging and FNA can be performed in a single procedure, unlike CT and CT-FNA, which require separate procedures. EUS-FNA should be considered in the majority of patients undergoing EUS to establish the diagnosis of cancer, determine histologic type, confirm lymph node histology, guide therapy, and assist with counseling of patients and referring physicians.

REFERENCES

- Gudjonsson B. Cancer of the pancreas: 50 years of surgery. *Cancer* 1987;60:2284-303.
- Abmad NA, Lewis JD, Ginsberg GG, Haller DG, Morris JB, Williams NN, et al. Long term survival after pancreatic resection for pancreatic adenocarcinoma. *Am J Gastroenterol* 2001;96:2609-15.
- Gress F, Hawes RH, Savides TJ, Ikenberry SO, Cummings O, Kopecky KK, et al. Role of EUS in the preoperative staging of pancreatic cancer: a large single-center experience. *Gastrointest Endosc* 1999;50:786-91.
- Palazzo L, Roseau G, Gayet B, Vilgrain V, Belghiti J, Fekete F, et al. Endoscopic ultrasonography in the diagnosis and staging of pancreatic adenocarcinoma. *Endoscopy* 1993;25:143-50.
- Tio TL, Tytgat GN, Cikota RJ, Houthoff HJ, Sars PR. Ampullopneumatic carcinoma: preoperative TNM classification with endosonography. *Radiology* 1990;175:455-61.
- Grimm H, Maydeo A, Soehendra N. Endoluminal ultrasound for the diagnosis and staging of pancreatic cancer. *Baillieres Clin Gastroenterol* 1990;4:869-87.
- Muller MF, Meyenberger C, Bertschinger P, Schaer R, Marincek B. Pancreatic tumors: evaluation with endoscopic US, CT, and MR imaging. *Radiology* 1994;190:745-51.
- Yasuda K, Mukai H, Nakajima M, Kawai K. Staging of pancreatic carcinoma by endoscopic ultrasonography. *Endoscopy* 1993;25:151-5.
- Ahmad NA, Lewis JD, Ginsberg GG, Rosato EF, Morris JB, Kochman ML. EUS in preoperative staging of pancreatic cancer. *Gastrointest Endosc* 2000;52:463-83.
- Nakaizumi A, Uehara H, Iishi H, Tatsuta M, Kitamura T, Kuroda C, et al. Endoscopic ultrasonography in diagnosis and staging of pancreatic cancer. *Dig Dis Sci* 1995;40:696-700.
- Yasuda K, Mukai H, Fujimoto S, Nakajima M, Kawai K. The diagnosis of pancreatic cancer by endoscopic ultrasonography. *Gastrointest Endosc* 1988;34:1-8.
- Rösch T, Braig C, Gain T, Feuerbach S, Siewert JR, Schusdziarra V, et al. Staging of pancreatic and ampullary carcinoma by endoscopic ultrasonography. *Gastroenterology* 1992;102:188-99.
- Rösch TP, Dittler HJ, Strobel K, Meining A, Schusdziarra V, Lorenz R, et al. Endoscopic ultrasound criteria for vascular invasion in the staging of cancer of the head of the pancreas: a blind reevaluation of videotapes. *Gastrointest Endosc* 2000;52:469-77.
- Brugge WR, Lee MJ, Kelsey PB, Schapiro RH, Warshaw AL. The use of EUS to diagnose malignant portal venous system invasion by pancreatic cancer. *Gastrointest Endosc* 1996;43:561-7.
- Snady H, Bruckner H, Siegel J, Cooperman A, Neff R, Kiefer L. Endoscopic ultrasonographic criteria of vascular invasion by potentially resectable pancreatic tumors. *Gastrointest Endosc* 1994;40:326-33.
- Rappaport DC. Helical CT applications in the thorax and abdomen. *Postgrad Med* 1998;104:105-14.
- Muller MF, Meyenberger C, Bertschinger P, Schaer R, Marincek B. Pancreatic tumors: evaluation with endoscopic US, CT, and MR imaging. *Radiology* 1994;190:745-51.
- Zeman RK, Cooper C, Zeiberg AS, Kladakis A, Silverman PM, Marshall JL, et al. TNM staging of pancreatic carcinoma using helical CT. *AJR Am J Roentgenol* 1997;169:459-64.
- Raptopoulos V, Steer ML, Sheiman RG, Vrachliotis TG, Gougoutas CA, Movson JS. The use of helical CT and CT angiography to predict vascular involvement from pancreatic cancer: correlation with findings at surgery. *AJR Am J Roentgenol* 1997;168:971-7.
- Diehl SJ, Lehmann KJ, Sadick M, Lachmann R, Georgi M. Pancreatic cancer: value of dual phase helical CT in assessing resectability. *Radiology* 1998;206:373-8.
- Midwinter MJ, Beveridge CJ, Wilsdon JB, Bennett MK, Baudouin CJ, Charnley RM. Correlation between spiral computed tomography, endoscopic ultrasonography and findings at operation in pancreatic and ampullary tumors. *Br J Surg* 1999;86:189-93.
- Legmann P, Vignaux O, Dousset B, Baraza AJ, Palazzo L, Dumontier L, et al. Pancreatic tumors: comparison of dual phase CT and endoscopic sonography. *AJR Am J Roentgenol* 1998;170:1315-22.
- Tierney WM, Francis K, Eckhauser F, Elta GH, Nostrant TT, Scheiman I. The accuracy of EUS and helical CT in the

- assessment of vascular invasion by peripapillary tumor. *Gastrointest Endosc* 2001;53:182-8.
24. Mertz HR, Sechopolous P, Delbeke D, Leach SD. EUS, PET, and CT scanning for evaluation of pancreatic adenocarcinoma. *Gastrointest Endosc* 2000;52:367-71.
 25. Buscail L, Pages P, Berthelemy P, Fourtanier G, Frexinos J, Escourrou I. Role of EUS in the management of pancreatic and ampullary carcinoma: a prospective study assessing resectability and prognosis. *Gastrointest Endosc* 1999;50:34-40.
 26. Ahmad NA, Kochman ML, Lewis JD, Kadish S, Morris JB, Rosato EF, et al. Endosonography is superior to angiography in the preoperative assessment of vascular involvement among patients with pancreatic carcinoma. *J Clin Gastroenterol* 2001;32:54-8.
 27. Ahmad NA, Lewis JD, Siegelman ES, Rosato EF, Ginsberg GG, Kochman ML. Role of endoscopic ultrasound and magnetic resonance imaging in the preoperative staging of pancreatic adenocarcinoma. *Am J Gastroenterol* 2000;95:1926-31.
 28. Cannon ME, Carpenter SL, Elta GH, Nostrant TT, Kochman ML, Ginsberg GG, et al. EUS compared with CT, magnetic resonance imaging, and angiography and the influence of biliary stenting on staging accuracy of ampullary neoplasms. *Gastrointest Endosc* 1999;50:27-33.
 29. Faigel DO, Ginsberg GG, Bentz JS, Gupta PK, Smith DB, Kochman ML. Endoscopic ultrasound-guided real-time fine-needle aspiration biopsy of the pancreas in cancer patients with pancreatic lesions. *J Clin Oncol* 1997;15:1439-43.
 30. Williams DB, Sahai AV, Aabakken L, Penman ID, van Velse A, Webb J, et al. Endoscopic ultrasound guided fine needle aspiration biopsy: a large single centre experience. *Gut* 1999;44:720-6.
 31. Voss M, Hammel P, Molas G, Palazzo L, Dancour A, O'Toole D, et al. Value of endoscopic ultrasound guided fine needle aspiration biopsy in the diagnosis of solid pancreatic masses. *Gut* 2000;46:244-9.
 32. Wiersema MJ, Norton ID, Clam JE. Role of EUS in the evaluation of pancreatic adenocarcinoma. *Gastrointest Endosc* 2000;52:578-81.
 33. Fritscher-Ravens A, Izbicki JR, Sriram PV, Krause C, Knoefel WT, Topalidis T, et al. Endosonography-guided fine needle aspiration cytology extending the indication for organ-preserving pancreatic surgery. *Am J Gastroenterol* 2000;95:2255-60.
 34. Mallery S, Centeno B, Hahn P, Warshaw AL, Brugge WR. Comparison of EUS-guided, CT-guided and intraoperative needle biopsy of pancreatic masses [abstract]. *Gastrointest Endosc* 1998;47:AB149.
 35. Tierney WM, Fendrick M, Hirth RA, Scheiman JM. The clinical and economic impact of alternative staging strategies for adenocarcinoma of the pancreas. *Am J Gastroenterol* 2000;95:1708-13.
 36. Harewood GC, Wiersema MJ. A cost analysis of endoscopic ultrasound in the evaluation of pancreatic head adenocarcinoma. *Am J Gastroenterol* 2001;96:2651-6.
 37. Hahn M, Faigel DO. Frequency of mediastinal lymph node metastases in patients undergoing EUS evaluation of pancreaticobiliary masses. *Gastrointest Endosc* 2001;54:331-5.